

# DEBRICHEM®

## A BEST PRACTICE DOCUMENT

NEED, APPLICATION AND EVALUATION



**SCAN FOR YOUR DIGITAL COPY**

# Contents

- S3 Foreword**  
Andrew Sharpe
- S4 Topical desiccating agent (DEBRICHEM): an accessible debridement option for removing biofilm in hard-to-heal wounds**  
Priti Bhatt, Andrew Sharpe, Karen Staines, Nicola Wallace and Amy Withers
- S12 Efficacy and safety of anti-infection topical desiccating agent (DEBRICHEM) in hard-to-heal wounds**  
John McRobert, Steven Jeffery and Debbie Delloson

## MA Healthcare

### Published by MA Healthcare Ltd

St Jude's Church, Dulwich Road, London, SE24 0PB, UK  
+44 (0)20 7738 6726  
[www.markallengroup.com](http://www.markallengroup.com)

Project editor: **Benjamin Wakefield**  
Project manager: **Angela Shaw**  
Associate publisher: **Tracy Cowan**  
Head of projects: **Chris Beck**  
Design: **Veesun Ho**  
Managing director: **Anthony Kerr**

### Produced by Mark Allen Medical Communications

[www.mamedcomms.com](http://www.mamedcomms.com)

To discuss partnering on case series documents,  
contact Anthony Kerr on +44 (0)7979 520828  
[anthony.kerr@markallengroup.com](mailto:anthony.kerr@markallengroup.com)

### © MA Healthcare Ltd 2024

All rights reserved. No reproduction, transmission or copying of this publication is allowed without written permission. No part of this publication may be reproduced, stored in a retrieval system, or transmitted in any form or by any means, mechanical, electronic, photocopying, recording, or otherwise, without the prior written permission of MA Healthcare or in accordance with the relevant copyright legislation.

### Supported by DEBx Medical BV

Although the editor, MA Healthcare Ltd and DebX Medical BV have taken great care to ensure accuracy, neither MA Healthcare Ltd nor DebX Medical BV will be liable for any errors of omission or inaccuracies in this publication.

### Declarations of interest

Andrew Sharpe received an honorarium for writing the foreword to this supplement. Payment was made to Pioneer Wound Healing & Lymphoedema Centres for data collection and to Accelerate. There are no other conflicts of interest to declare.

# Foreword

Andrew Sharpe

**H**ard-to-heal wounds present a complex terrain for wound-care specialists with a commitment to advancing patient care.

The burden of wounds is growing, with an estimated 7% of the population having an active lower limb or foot ulcer.<sup>1</sup> The economic burden of wound care stands at £8.3 billion per year<sup>1</sup> and is getting more expensive. Clinicians working in wound care lack access to the diagnostic equipment, specialist provision and staff resource to manage complex caseloads. Meanwhile, there is little time to improve wound-care education, and specialist referrals are often delayed. All this can leave patients with prolonged discomfort and compromised quality of life, while clinicians can feel they are on the frontline of a constant battle. This context gives particular importance to the emergence of innovative solutions that can revolutionise approaches to healing and redefine standards of care.

Professionals in this field are challenged by hard-to-heal wounds with complex aetiologies that resist traditional healing efforts. Common underlying conditions include prolonged exposure to pressure, diabetes and arterial/venous insufficiency, with infected diabetic foot ulcers (DFUs) and ischaemic leg ulcers being leading causes of non-traumatic lower-limb amputation.<sup>2</sup> These issues often present in combination and with other comorbidities. To help these wounds heal, the underlying causes must be addressed with appropriate interventions, as with glycaemic control and offloading for DFUs; repositioning and redistribution for pressure ulcers; revascularisation for ischaemic ulcers; and compression for VLU.

Treating these wounds needs a multifaceted approach that also addresses local impediments to healing and other holistic considerations.<sup>3</sup> Central to this approach is effective wound-bed preparation,<sup>4</sup> a cornerstone of which is debridement, the removal of non-viable tissue, which is a breeding ground for biofilm and infection and thus impedes healing.<sup>5</sup> The traditional gold-standard methods of surgical and sharp debridement boast undeniable efficacy, but their accessibility is constrained by the need for specialised training and facilities, limiting their widespread adoption. More accessible alternatives, such as enzymatic, mechanical and autolytic debridement, can be slower and less effective.<sup>6</sup> Hence, there is a need for new methods of debridement that are as accessible as they are effective.

The topical desiccating agent (TDA) DEBRICHEM® is a new debridement option with positive indications for clinicians and patients alike. Its unique mode of action rapidly and efficiently removes non-viable tissue, streamlining the debridement process to expedite

healing.<sup>7</sup> TDA has the potential to mitigate risk of infection and need for antibiotics, which is particularly valuable when many clinicians are concerned about antimicrobial stewardship. Moreover, TDA requires minimal training and can be performed by a range of practitioners in many settings. The convenience of a single application sets TDA apart, potentially enhancing cost-effectiveness and patient adherence, while avoiding the need for recurrent interventions.

The first part of this supplement reviews the need for new debridement options, introduces TDA's mode of action and presents best-practice recommendations for its application, with answers to frequently asked questions. The second part is an evaluation of the efficacy and safety of TDA in a real-world clinical setting, evidencing reduction of non-viable tissue, proliferation of healthy granulation tissue and alleviation of clinical signs of infection, as well as a favourable safety profile and high levels of patient and clinician satisfaction.

This supplement adds to the compelling evidence of TDA's potential to reduce infection and promote healing.<sup>7,8</sup> It is hoped that this debridement option will have a transformational impact on wound care and offer hope for people living with hard-to-heal wounds. TDA is testament to the power of innovation, the embrace of which is paramount to navigating the evolving wound care landscape. Enhancing patient outcomes and quality of life will require a willingness and commitment from clinicians, researchers and patients to engage with new approaches to wound care, push the boundaries of possibility and proactively adopt change.

## References

1. Guest JF, Fuller GW, Vowden P. Cohort study evaluating the burden of wounds to the UK's National Health Service in 2017/2018. *BMJ Open*. 2020; 10(12):e045253. <https://doi.org/10.1136/bmjopen-2020-045253>
2. Ahmad N, Thomas GN, Gill P, Torella F. The prevalence of major lower limb amputation in the diabetic and non-diabetic population of England 2003-2013. *Diabetes Vasc Dis Res*. 2016;13(5):348-353. <https://doi.org/10.1177/1479164116651390>
3. Bianchi T, Wolcott Rd, Peghetti A et al. Recommendations for the management of biofilm. *J Wound Care*. 2016; 25(6):305-317. <https://doi.org/10.12968/jowc.2016.25.6.305>
4. Atkin L, Bučko Z, Montero EC et al. Implementing TIMERS: the race against hard-to-heal wounds. *J Wound Care*. 2019; 28(S3a):S1-S50. <https://doi.org/10.12968/jowc.2019.28.Sup3a.S1>
5. Swanson T, Ousey K, Haesler E et al. IWII wound infection in clinical practice consensus document. *J Wound Care*. 2022; 31(S12):S10-S21. <https://doi.org/10.12968/jowc.2022.31.Sup12.S10>
6. Strohal R, Dissemond J, O'Brien J et al. Debridement: an updated overview and clarification of the principle role of debridement. *J Wound Care*. 2013; 22(1):5. <https://doi.org/10.12968/jowc.2013.22.Sup1.S1>
7. Cogo A, Bignozzi AC, Hermans MHE, Quint BJ, Snels JP, Schultz G. A desiccation compound as a biofilm- and necrosis-removing agent: a case series. *J Wound Care*. 2022; 31(10):816-822. <https://doi.org/10.12968/jowc.2022.31.10.816>
8. Bennett E, Bhatt P, Hermans H et al. Tackling hard-to-heal wounds with a new option for chemical debridement. *J Wound Care*. 2023; 32(S3b):S3. <https://doi.org/10.12968/jowc.2023.32.Sup3b.S3>

Andrew Sharpe, Advanced Podiatrist, Salford Care Organisation, Northern Care Alliance NHS Foundation Trust

# Topical desiccating agent (DEBRICHEM): an accessible debridement option for removing biofilm in hard-to-heal wounds

Priti Bhatt, Andrew Sharpe, Karen Staines, Nicola Wallace and Amy Withers

## Abstract

It is now assumed that all hard-to-heal wounds contain biofilm. Debridement plays a key role in wound-bed preparation, as it can remove biofilm along with the devitalised tissue, potentially leaving a clean wound bed that is more likely to progress towards healing. The gold standard methods of debridement (surgical and sharp) are the least used, as they require specialist training and are often not readily available at the point of need. Most other methods can be used by generalists but are slower. They all need regular applications. The topical desiccating agent DEBRICHEM is an innovative alternative, as it is fast, effective and can be used in all clinical settings, as well as typically requiring only a single use. This article describes best practice for achieving optimal outcomes with its use.

Among healthcare professionals, there is a growing awareness and concern about the impactful role of biofilm in wound infection and chronicity.<sup>1-3</sup> An expanding body of scientific literature has been describing the often devastating effect of biofilms on wound healing, including increased risks of delayed healing, infection, sepsis and death.<sup>3,4</sup>

## Burden of biofilm

Biofilms are complex microbial communities of multiple species of bacteria and fungi.<sup>3,5</sup> These microorganisms synthesise and secrete a protective matrix, known as an extracellular polymeric substance (EPS), which firmly attaches the biofilm to a living or non-living surface.<sup>5</sup> Mature biofilm is resistant to antiseptics and even antibiotics, which is particularly concerning in light of antibiotic resistance.<sup>6</sup> Even when biofilm is removed, the presence of both free-moving (planktonic) and fixed (sessile) bacteria in the wound mean that it can reform rapidly (within 2-4 days from initial colonisation), resulting in a persistent cycle of re-formation and thus prolonged infection.<sup>7</sup>

If not eradicated, biofilm will result in covert wound infection.<sup>3</sup> Biofilm development has been linked to the persistent inflammatory state common with

hard-to-heal wounds (similar to inflammatory patterns seen in other chronic conditions, such as cystic fibrosis, periodontal disease and inflammatory bowel disease).<sup>8,9</sup> Hard-to-heal wounds generally share similar biochemical inflammatory markers, such as high levels of proteases (including matrix metalloproteinases) and reactive oxygen species, as well as diminished growth factor activity and reduced cell numbers. These processes are likely to be caused by the bacteria in the wound, which can delay the phases of granulation and epithelialisation that are essential to wound healing.<sup>10-13</sup>

Biofilm is not visible to the naked eye, and it cannot be conclusively detected by visible assessment, with many healthy-looking wounds having been demonstrated to contain biofilm.<sup>9</sup> Even biochemical detection of biofilm is challenging, because there is no specific molecular signature, with a biofilm's matrix components varying according to the microorganisms and environment present.<sup>14</sup> However, 78% of all hard-to-heal wounds are thought to have biofilms,<sup>9</sup> and it is now widely accepted that all hard-to-heal wounds should be considered to contain some amount of biofilm and be affected by its presence.

**Priti Bhatt**, Community Tissue Viability Lead, Guy's and St Thomas' NHS Foundation Trust

**Andrew Sharpe**, Advanced Podiatrist, Salford Care Organisation, Northern Care Alliance NHS Foundation Trust

**Karen Staines**, Director of Research and Wound Care, Accelerate

**Nicola Wallace**, Leg Ulcer Clinical Nurse specialist, Central London Community Healthcare NHS Trust

**Amy Withers**, Lead Tissue Viability Nurse, Acute Services, Manchester University NHS Foundation Trust

Removal of biofilm is essential to successfully clear infection, treat hard-to-heal wounds and break the cycle of re-infection. Consequently, biofilm management is of central importance to wound care.<sup>6</sup> Biofilm removal and management requires a multi-targeted approach, including a range of holistic factors.<sup>6,10</sup> Much of this antibiofilm approach falls under the concept of wound bed preparation (WBP), which includes cleansing and debridement. WBP should be undertaken at each dressing change, similar to undertaking personal and dental hygiene. WBP has become instrumental to wound care, with several frameworks available for assessment and implementation.<sup>15-18</sup>

**Debridement**

The cornerstone of WBP is debridement. Debridement is the removal of debris, dressings and non-viable (devitalised) tissue from within a wound bed, where biofilm is particularly likely to be embedded.<sup>3</sup> Debridement aims to remove biofilm to reduce inflammation and facilitate normal tissue repair.<sup>5,19,20</sup> By reducing the bioburden, debridement provides a window of opportunity to increase the effectiveness of topical strategies.<sup>21</sup> To prevent biofilm re-formation, it is imperative for debridement to be undertaken regularly and persistently at the point of need.<sup>3</sup>

Debridement is typically targeted at non-viable tissue types, such as slough and necrotic tissue, which are a prominent feature of hard-to-heal wounds and have several detrimental effects (Box 1).<sup>5</sup> Slough, which is formed from the waste products of natural antimicrobial processes (such as dead leucocytes), is thought to share many of the same characteristics as biofilm, acting as an area of attachment for microbes and causing persistent inflammation.<sup>5</sup>

There are a large range of options for debridement, which vary in terms of their invasiveness, selectiveness, efficacy and training required, with each option having advantages and disadvantages (Figure 1).<sup>22</sup> These include the following:

- **Surgical debridement** is a relatively effective approach involving the use of surgical instruments, usually under anaesthesia in the acute setting, which is a significant limiting factor carrying all the risks associated with surgical procedures.
- **Sharp debridement** involves the use of scissors, a scalpel or a curette, and is fast and effective. It can be undertaken in a variety of settings, but it requires specialist training and is not readily available at point of need.
- **Ultrasonic debridement** involves the application of low-frequency energy to debride non-viable tissue. Although painless and selective, it requires specialist training and expensive equipment.
- **Hydrosurgical debridement** involves the high-pressure application of liquid to ‘lavage’ the wound

**Box 1. Detrimental effects of non-viable tissue<sup>5</sup>**

**Infection**

- Attraction of microorganisms to the wound site
- Harboured of biofilms
- Raised risk of infection
- Stalled normal wound healing

**Assessment**

- Mimicking or disguising infection
- Obscuring the area and depth of the wound
- Impeding effective swabbing for microbial analysis

**Quality of life**

- Pain
- Increased exudate
- Risk to periwound area
- Malodour
- Sleep deprivation
- Social isolation






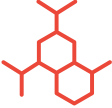


and is similar in effect to sharp debridement. It can be painful and has the potential risk of increasing infection and disseminating bacteria into the environment. Specialist training and expensive equipment and consumables are required.

- **Larval debridement** is a very effective debridement method using the larvae (maggots) of the green bottlefly to ingest non-viable tissue and microbes. It requires only limited training, and it is available in all clinical settings. It usually takes around 3–9 days to work, with each treatment lasting for 3–5 days; some patients require more than one treatment.<sup>23</sup> However, larval debridement is often more expensive than sharp, mechanical and autolytic methods, and can have psychological barriers. It is not suitable for very dry or very wet wounds.
- **Enzymatic debridement** involves use of topical enzymes to dissolve necrotic tissue in the wound. It is considered relatively expensive and is not suitable for large and/or infected wounds.
- **Mechanical debridement** uses monofilament cloths, pads or wipes to remove specific tissue types from the wound. It is widely used by specialists and generalists due to its ease of use and relatively low cost. However, it is relatively slow and unsuitable for dry eschar, and it can be painful.
- **Autolytic debridement** involves the use of moist dressings to help the body digest and remove necrotic tissue. It is easy to use by all wound care clinicians but is time-consuming and carries the increased risk of invasive infection. There is also limited evidence of its effect of biofilm.

Therefore, it is evident that these established and widely implemented methods of debridement do not offer an ideal combination of fast, effective, efficient

**Figure 1. Debridement: lifting the burden of hard-to-heal wounds**

Each year, the NHS spends £8.3 billion managing 3.8 million wounds; **£5.6 billion of this is spent on hard-to-heal wounds.**<sup>31</sup> Wound healing is often delayed by the presence of non-viable, sloughy or necrotic tissue, which can harbour biofilm and increase the risk of infection.<sup>3,32</sup> **Removing non-viable tissue via debridement is essential to helping these wounds heal.** Debridement and wound bed preparation should be part of a holistic programme of care, alongside treating the aetiology, managing comorbidities and addressing psychosocial factors.<sup>7</sup> **There are several debridement methods, each with advantages and drawbacks.**<sup>3</sup>

 <p><b>Surgical debridement</b> Excision in theatre with surgical tools</p> <ul style="list-style-type: none"> <li>✓ Highly effective</li> <li>✓ Very fast</li> <li>✗ Requires expensive surgical training and hospital facilities</li> <li>✗ Invasive, with need for anaesthesia and risk of complications</li> </ul>	 <p><b>Sharp debridement</b> Excision with a blade (scalpel, curette or scissors)</p> <ul style="list-style-type: none"> <li>✓ Highly effective</li> <li>✓ Very fast</li> <li>✓ Available to non-surgeons outside hospital</li> <li>✗ Needs specialist training</li> <li>✗ Potentially painful</li> <li>✗ Invasive, with risk of damage to healthy tissue</li> </ul>	 <p><b>Ultrasonic debridement</b> Application of low-frequency wavelengths</p> <ul style="list-style-type: none"> <li>✓ Reduces microbial bioburden</li> <li>✓ Relatively painless</li> <li>✓ Selective</li> <li>✗ Requires specialist training and equipment</li> <li>✗ High cost</li> </ul>	 <p><b>Hydrosurgical debridement</b> Washout (lavage) with a high-pressure liquid</p> <ul style="list-style-type: none"> <li>✓ Targetable</li> <li>✓ Effective against biofilm</li> <li>✗ Requires specialist training and equipment</li> <li>✗ Potentially painful</li> <li>✗ Invasive, with risk of damage to healthy tissue and increased risk of infection</li> </ul>
 <p><b>Larval debridement</b> Ingestion by live, sterile fly larvae</p> <ul style="list-style-type: none"> <li>✓ Rapid</li> <li>✓ Requires minimal training</li> <li>✗ High cost</li> <li>✗ Potentially psychologically offputting for patients</li> <li>✗ Unsuitable for hard dry necrotic tissue</li> </ul>	 <p><b>Enzymatic debridement</b> Dissolution via biochemical enzymes</p> <ul style="list-style-type: none"> <li>✓ Dissolves necrotic tissue</li> <li>✓ Effective in a moist environment</li> <li>✗ Relatively expensive</li> <li>✗ Unsuitable for large or infected wounds</li> <li>✗ Slow</li> </ul>	 <p><b>Mechanical debridement</b> Abrasion with a cloth or pad</p> <ul style="list-style-type: none"> <li>✓ Selective effect</li> <li>✓ Low cost and requires minimal training</li> <li>✗ Less effective than gold-standard options</li> <li>✗ Potential for discomfort</li> <li>✗ Unsuitable for eschar and thick fibrous slough</li> </ul>	 <p><b>Autolytic debridement</b> Natural breakdown, encouraged by therapeutic dressings</p> <ul style="list-style-type: none"> <li>✓ Minimally invasive and rarely painful</li> <li>✓ Widely available and requires minimal training</li> <li>✗ Time-consuming</li> <li>✗ Limited impact on biofilm</li> </ul>

Despite this range of options, there remains a need for a method of debridement that can rapidly and effectively remove infection and biofilm, while being available to a wide range of clinicians in non-hospital settings.

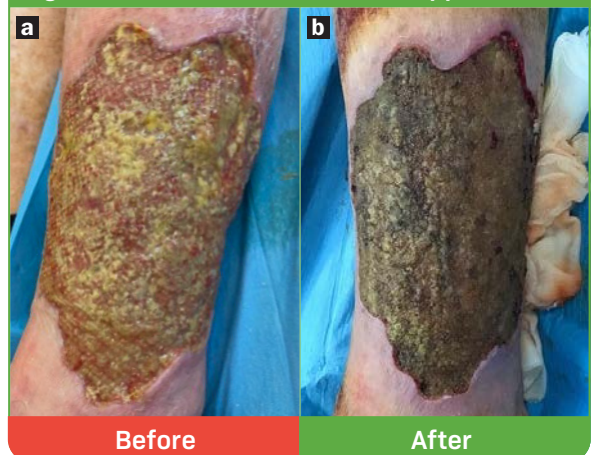
and patient-specific treatment in all care settings at the point of patient need. Although some existing methods can be used in combination, the availability of alternative approaches could make this vital component of WBP more widely available for the management of biofilms and resolution of hard-to-heal wounds.

**Presenting a pioneering topical chemical desiccating agent**

The topical desiccating agent (TDA) DEBRICHEM (DEBx Medical BV, Amsterdam, Netherlands) is a pioneering option for debridement.<sup>24</sup> TDA is approved as a single-use class IIB medical device and indicated for infected non-surgical wounds, including diabetic foot ulcers, venous leg ulcers and pressure ulcers.

In clinical case studies, the use of TDA has demonstrated reductions in pain, malodour and

**Figure 2. Before (a) and after (b) application**



exudate levels, as well as the number of wound infections requiring antibiotic medication, resulting in a subsequent improved quality of life.<sup>24-28</sup> This is indicative of rapid elimination of biofilm, sustained reduction in bacterial bioburden and prevention of biofilm re-formation in the wound.<sup>24-28</sup> Alongside this clinical efficacy, TDA is also quick to apply, easy to use and typically requires only a single application, making it a cost-effective option.<sup>27-29</sup>

**Mode of action**

TDA is an acid gel that contains methanesulfonic acid, dimethylsulfoxide and amorphous silica. This acidic compound has a selective hygroscopic (desiccating) property that extracts water molecules from any biological material with a sufficiently high water content. Consequently, TDA acts on non-viable tissue and biofilm, which is composed of between 70% and 90% water,<sup>30</sup> but within a 60-second exposure time it does not affect viable tissue, such as the external epidermal layer of the skin, which has a lower water content.<sup>29</sup>

When the gel makes contact with the wound bed, the acid immediately extracts water from non-viable tissue and biofilm. This produces a thermal energy up to 1500 JK/mol, which is absorbed by proteins and

sugars in the target tissues, breaking bonds between their molecular components. This rapid dehydrating effect takes no more than 60 seconds to desiccate non-viable tissues and denature their microbial constituents.<sup>24</sup>

After the water has been extracted from the target tissues; the remaining free carbon in the desiccated material causes rapid carbonisation and oxidation, with an immediate effect. The wound bed may become visibly much darker in colour and drier in appearance (Figure 2).<sup>26</sup> In clinical practice, visible carbonisation occurs to a greater or lesser degree depending on the amount of water that was present in the affected tissues. A higher level of water creates a greater reaction to the acid, which generates more energy and thus more carbon, causing the different degrees of dark tissue that might be seen in the wound bed.

TDA's acidic action is neutralised and stopped when rinsed with saline. The short application time should ensure the periwound skin and healthy wound tissue are not damaged. Some of the desiccated material, which includes slough, biofilm and inflammatory proteins, should come off during rinsing. Any remaining desiccated material should eventually separate and detach from the underlying wound bed and gradually lift in due time.<sup>24,27</sup> After this, enough non-viable tissue and biofilm should be removed to recommence the processes of granulation and epithelialisation that are essential for healthy wound healing.<sup>24,26,28</sup>

**Box 2. Contraindications and cautions**

**Contraindications**

- Ischemic wounds\*
- Neoplastic wounds
- Burns
- Exposed tendon or bone (underlying structures)
- Underlying abscess or fasciitis that requires incision/excision and drainage
- Unexplored tunnelling or undermining (due to risk to underlying organs)
- Underlying osteomyelitis
- Allergy or intolerance to ingredients
- Implants and vascular grafts

**Cautions**

- Exposed bones
- Eschar (unless removed)
- Wounds near the facial region (mouth, nose and eyes to be avoided)
- Wounds near the anus, vagina, penis or testicles
- Ongoing cancer treatment (should be considered on a case-by-case by the multidisciplinary team)

\*Multidisciplinary teams in a specialist setting can consider patients with ischemic wounds for treatment with topical desiccation agent as appropriate

**Patient selection**

TDA is indicated for use for the debridement and treatment of the wound bed of non-surgical, infected

**Box 3. Pain management**

The acidic action and desiccation effect achieved with topical debridement agent (TDA) can cause brief pain during and after application.<sup>24,26</sup> Therefore, it is recommended to mitigate this pain as much as possible. Baseline pain should be assessed during cleansing and dressing change using a pain assessment tool such as the visual analogue scale (VAS),<sup>33</sup> and any concerns regarding potential pain during the procedure should be determined and addressed.

Before application of TDA, appropriate local anaesthetic should be applied according to guidance.<sup>34</sup> For example, topical lidocaine and prilocaine cream can be spread over the wound and periwound and occluded with film to aid absorption.<sup>35</sup> Pain management should follow local policy, formulary and relevant instructions for use.

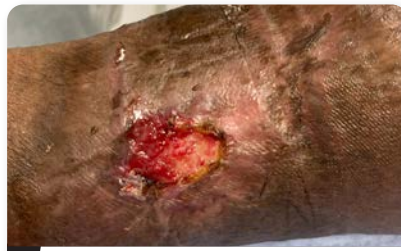As an additional option, just before application of the full desired amount of TDA, the anaesthetic effect could be tested by applying two drops of TDA and leaving for 10 seconds before rinsing off with normal saline. If the test is tolerable for the patient, application can continue. If the test is intolerable for the patient, there may be a need to escalate the strategy for pain management. Greater analgesia may be achieved with subcutaneous lidocaine injection, peripheral nerve block or systemic narcotics, according to local policy, the clinical setting and the practitioner's level and relevant qualifications.

After the procedure, procedural pain should start to dissipate within 5-60 minutes. If pain persists, additional analgesia can be considered.

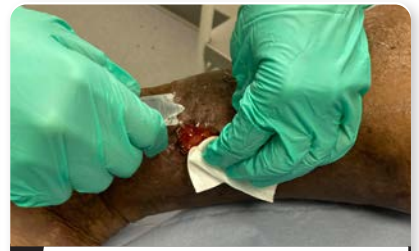
Figure 3. Step-by-step guide to application of a topical desiccating agent (TDA), DEBRICHEM



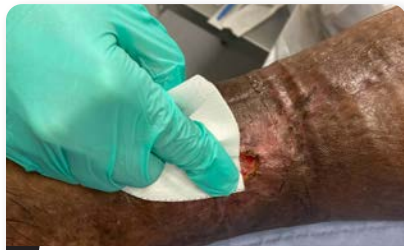1. Put on gloves and goggles



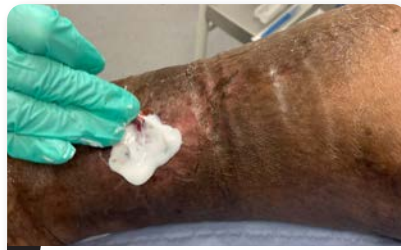2. Uncover the wound



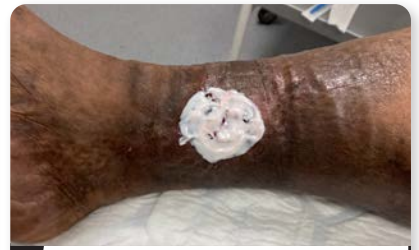3. Cleanse the wound and periwound



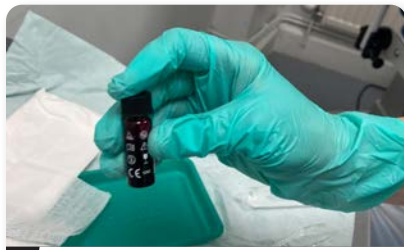4. Dry the wound with dry gauze



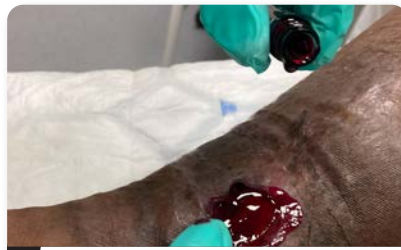5. Apply topical analgesic to wound and periwound (unless neuropathic)



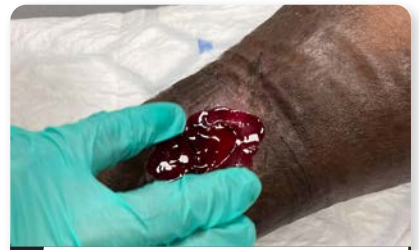6. Spread on wound and periwound and remove before applying TDA



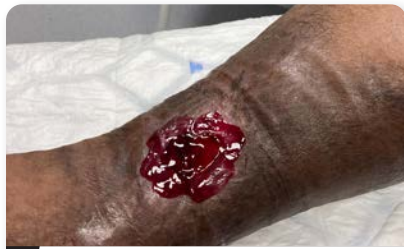7. Shake the vial



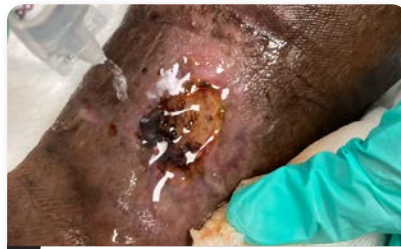8. Pour TDA onto the wound



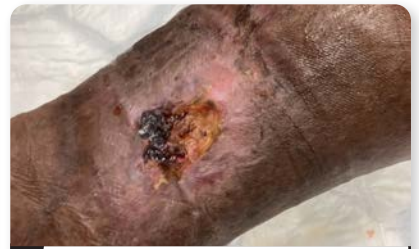9. Spread TDA evenly over the wound and periwound skin



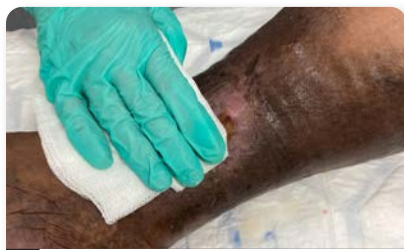10. Leave TDA on wound for 60 seconds from first moment of application



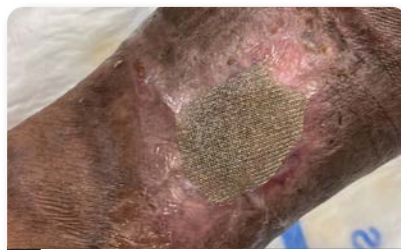11. Wash off with ample saline or sterile water



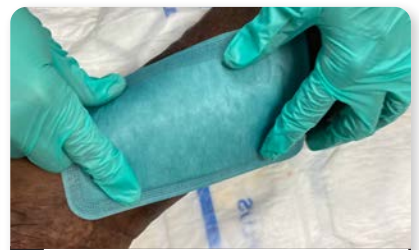12. Expect a darker, drier wound bed



13. Remove loose debris with dry gauze



14. Apply primary dressing according to the local wound-care protocol



15. Apply secondary dressing according to the local wound-care protocol



wounds and/or wounds containing biofilm and/or non-viable tissue (including sloughy or relatively wet necrotic tissue), including, among others, diabetic foot ulcers, arterial/venous leg ulcers and pressure ulcers.<sup>24</sup> Any dry, crusty, full-thickness necrotic tissue (eschar) must be removed before application, as its water content is too low for TDA to be effective. There are several contraindications and cautions (*Box 2*). Eligible patients must be informed of all the effects of TDA to obtain valid consent, as well as avert any concerns regarding the changes caused by the dehydration and carbonisation to the wound bed immediately following the treatment.

## Application

### Preparation

TDA should be used in combination with standard best-practice wound care. Prior to application of TDA, the clinician should wear suitable personal protective equipment. Then the wound bed and surrounding skin should be cleansed, to remove excess exudate, debris, wound dressing components and creams. After this, the wound surface should be dried with dry gauze. Analgesia can now be applied, if required (*Box 3*) and, then once it has taken effect, removed before TDA application.

### Procedure

Clinicians applying TDA must carefully and exactly follow the simple instructions for use (*Figure 3, overleaf*) and best-practice recommendations (*Box 4*). This is essential to effectively trigger the mode of action, minimise patient discomfort and ensure patient and clinician safety. TDA is applied with the following steps:

- Shake vial vigorously for 30 seconds before opening (each vial can cover an area of around 100 cm<sup>2</sup>)
- Assess the need for pain management and apply analgesic where necessary
- Apply gel to completely cover the wound bed and 1 cm of periwound skin
- Spread gel evenly on the wound and periwound skin, applying light pressure using a gloved finger
- Leave gel in situ for 60 seconds from the first moment of application
- Allow the wound to become drier and darken (as this is due the carbonisation and effect of TDA on biofilm)
- After 60 seconds, rinse the wound with plenty of free-flowing saline or sterile water
- Remove any remaining loose debris with dry gauze
- Apply a primary and secondary dressing according to local wound-care protocol.

### Follow-up

Any procedural pain present after application should start to dissipate within 5–60 minutes. If it persists beyond this, additional analgesia can be considered.

The patient should continue to receive standard best-practice wound care, including WBP, moist wound healing and treatment of any underlying cause of the wound (such as venous hypertension), according to local protocol.<sup>26</sup> This should achieve optimal benefits from TDA and ensure that wound biofilm and bioburden remain well controlled.

Over the following weeks, clinicians should monitor the tissue types in the wound bed, signs of infection and other markers of wound healing to gauge the effects of TDA. One treatment of TDA is usually sufficient to remove infection and expedite wound healing.

### Conclusion

Biofilms and infection have a devastating effect on wounds, resulting in the risk of non-healing, sepsis and even death, with a negative impact on the quality of life of patients who live with pain, malodour, excessive exudate and wound chronicity.<sup>3</sup> Therefore, gold-standard WBP incorporates debridement, which must be undertaken regularly and at the point of clinical need to break the continuous biofilm cycle and enable the wound to progress to granulation and epithelialisation.<sup>16</sup>

TDA overcomes many of the remaining challenges in the quest to achieve an optimum method of debridement. The acidic gel offers a unique and effective mode of action based on the rapid desiccation of non-viable tissue and biofilm to facilitate its removal.<sup>24,25,28,29</sup> Correct and appropriate application of TDA can be as fast and effective as surgical and/or sharp debridement. Moreover, TDA is a reliable, efficient and cost-effective approach that usually only requires a single application.

#### Box 4. Questions and answers by the author panel regarding topical desiccating agent (TDA)

##### Q How can I determine that TDA is safe to apply?

In the panel's experience, TDA has proven to be a safe and successful option for debridement and biofilm treatment, when indicated, such as hard-to-heal leg ulcers subsequently treated with compression bandaging.

##### Q What training is required to use TDA?

Unlike alternative methods such as sharp or surgical debridement, TDA does not require any additional formal training or competency completion, beyond following the clear instructions provided. Initial interdisciplinary discussion with tissue viability, podiatry or plastics teams and other wound-care specialists will help ensure appropriate usage, as per local protocol.

**Box 4. Questions and answers by the author panel regarding topical desiccating agent (TDA), continued****Q How should I inform patients about TDA?**

The patient information literature provided by the manufacturer is a good resource to help healthcare professionals reiterate explanations of the barriers to wound healing, such as biofilm. It is essential to fully explain and manage the patient's expectations about pain during application, mentioning that, in most cases, procedural pain will subside considerably within the first hour post-procedure. It is best to discuss the benefits of using the product and procedure at an appointment prior to application to enable the patient to consider the information provided, ask questions and give their informed consent on the day of application.

**Q How do I protect myself when using TDA?**

TDA can be used safely, with no harm to clinicians or patients, by wearing normal personal protective equipment (PPE), including goggles, gloves and an apron.

**Q How do I prepare the wound before application, and what if eschar is present?**

TDA, which reacts with water in the wound bed, is ineffective on a dry surface (hence why it is safe on intact skin). Therefore, prior to application, any dry necrotic tissue (including eschar) should first be removed with sharp or, if appropriate, autolytic debridement. The wound should then be cleansed and any loosened debris removed with gauze.

**Q How can I minimise any procedural pain to the patient?**

Like sharp debridement, TDA application causes pain in sensate patients. Following the 60-second application, this pain diminishes significantly in the first hour and will disappear over the next 24 hours. Pain on application can be minimised with a topical anaesthetic, such as lidocaine and prilocaine 5% cream, which is well tolerated by patients. Oral analgesia or a local anaesthetic could also be considered, but this is not standard practice.

**Q How can I get best outcomes with TDA?**

TDA should only be used on appropriate wounds with signs of covert or overt infection or suspected biofilm and no contraindications present. The clinician should ensure that the patient fully understands what to expect during and after application, especially regarding pain levels and tissue discolouration. Before application, the following should be close at hand: adequate pain relief, ample rinsing agent (sterile water or saline) and, ideally, a vessel to catch the copious liquid runoff. During application, TDA should be spread over the entire wound bed, edges and periwound skin to eliminate all bacteria in one application. An additional person in the room can help the applying clinician follow the correct procedure within the 1-minute timeframe.

**Q How can I tell from the outset that TDA is working?**

There will be an initial discolouration of the wound bed, which will turn an ashen colour as the bacteria, slough and wound exudate are dehydrated. This is a process of carbonisation, where TDA reacts with the water in the wound bed and leaves behind carbon. The other layer of the wound will become dry and flaky before coming away to reveal pink healthy granulation tissue beneath. After this, the wound should begin to decrease in size.

**Q What follow-up treatment is needed after application of TDA?**

To monitor treatment success, patients should be seen within 7 days of application and monitored as per local guidelines. Clinical outcome measures include removal of non-viable tissue and increase in granulation tissue, as well as reductions in wound size and general wound-related pain. It may take longer than a week for the wound tissue to show any improvement. If there is no improvement in 6–8 weeks, a second application can be considered.

**Q Is a single application usually sufficient?**

In the experience of the panel, a single application of TDA has a strong enough antibiofilm effect to restart the healing process in hard-to-heal wounds, including leg ulcers that have been stalled for many years.

**Q In what circumstances might it be necessary to reapply TDA?**

TDA may need to be reapplied if a wound that has shown initial improvement before starting to show new signs of infection, such as stalled healing. This is more prevalent where there is some level of underlying vascular (venous or arterial) disease that cannot be optimally managed, such as patients who cannot tolerate compression or require vascular surgery.

**Q How can I determine if TDA will be cost-effective?**

Patients should be assessed on a case-by-case basis for their suitability for TDA. The cost of TDA (and anaesthetic) should be weighed against the clinical and holistic outcomes of single-application rapid debridement. These outcomes should be compared with the patients' wound history during previous treatments, considering the typical time it takes to move a wound forward on the healing trajectory. Outcomes include presence of biofilm, episodes of local infection and need for referral into secondary care for surgical debridement. Other factors affecting cost and quality of life include number of patient visits, clinic time for application, use of additional modalities and frequency of dressing changes.

However, the most significant advantage of using TDA is that it is available at the point of clinical need in any clinical setting, without the need for specialist training and/or hospital admission.

## References

- Haesler E, Swanson T, Ousey K, Carville K. Clinical indicators of wound infection and biofilm: reaching international consensus. *J Wound Care*. 2019; 28(S3b):s4-s12. <https://doi.org/10.12968/jowc.2019.28.Sup3b.S4>
- Murphy C, Atkin L, Hurlow J, Swanson T, de Ceniga MV. Wound hygiene survey: awareness, implementation, barriers and outcomes. *J Wound Care*. 2021; 30(7):582-590. <https://doi.org/10.12968/jowc.2021.30.7.582>
- Swanson T, Ousey K, Haesler E et al. IWII wound infection in clinical practice consensus document. *J Wound Care*. 2022; 31(S12):S10-s21. <https://doi.org/10.12968/jowc.2022.31.Sup12.S10>
- Metcalf DG, Bowler PG. Biofilm delays wound healing: a review of the evidence. *Burns Trauma*. 2013; 1(1):2321-3868.113329. <https://doi.org/10.4103/2321-3868.113329>
- Percival SL, McCarty SM, Lipsky B. Biofilms and wounds: an overview of the evidence. *Adv Wound Care*. 2015; 4(7):373-381. <https://doi.org/10.1089/wound.2014.0557>
- Bianchi T, Wolcott Rd, Peghetti A et al. Recommendations for the management of biofilm: a consensus document. *J Wound Care*. 2016; 25(6):305-317. <https://doi.org/10.12968/jowc.2016.25.6.305>
- Atkin L, Bućko Z, Conde Montero E et al. Implementing TIMERS: the race against hard-to-heal wounds. *J Wound Care*. 2019; 23(S3a):S1-s50. <https://doi.org/10.12968/jowc.2019.28.Sup3a.S1>
- Fazli M, Bjarnsholt T, Kirketerp-Møller K et al. Quantitative analysis of the cellular inflammatory response against biofilm bacteria in chronic wounds. *Wound Repair and Regeneration*. 2011; 19(3):387-391. <https://doi.org/10.1111/j.1524-475X.2011.00681.x>
- Malone M, Bjarnsholt T, McBain AJ et al. The prevalence of biofilms in chronic wounds: a systematic review and meta-analysis. *J Wound Care*. 2017; 26(1):20-25. <https://doi.org/10.12968/jowc.2017.26.1.20>
- Fletcher J, Atkin L, Barrett S, Chadwick P, King B. Making day-to-day management of biofilm simple. *Wounds UK*. 2017. <https://tinyurl.com/3fr92b85> (accessed 11 March 2024)
- Lazaro JL, Izzo V, Meaume S, Davies AH, Lobmann R, Uccioli L. Elevated levels of matrix metalloproteinases and chronic wound healing: an updated review of clinical evidence. *J Wound Care*. 2016; 25(5):277-287. <https://doi.org/10.12968/jowc.2016.25.5.277>
- Nunan R, Harding KG, Martin P. Clinical challenges of chronic wounds: searching for an optimal animal model to recapitulate their complexity. *Dis Model Mech*. 2014; 7(11):1205-1213. <https://doi.org/10.1242/dmm.016782>
- Warriner R, Burrell R. Infection and the chronic wound: a focus on silver. *Advances in Skin & Wound Care*. 2005; 18 Suppl 1:2-12. <https://doi.org/10.1097/00129334-200510001-00001>
- Alavi M, Stojadinovic A, Izadjoo M. An overview of biofilm and its detection in clinical samples. *J Wound Care*. 2012; 21(8):376-383. <https://doi.org/10.12968/jowc.2012.21.8.376>
- Protz K, Drouard-Segard M. Triangle of wound assessment made easy. *Wounds Int*. 2015. <https://woundsinternational.com/made-easy/triangle-of-wound-assessment-made-easy/> (accessed 11 March 2024)
- Atkin L, Bućko Z, Montero EC et al. Implementing TIMERS: the race against hard-to-heal wounds. *J Wound Care*. 2019; 28(S3a):S1-S50. <https://doi.org/10.12968/jowc.2019.28.Sup3a.S1>
- Schultz G, Bjarnsholt T, James GA et al. Consensus guidelines for the identification and treatment of biofilms in chronic nonhealing wounds. *Wound Repair and Regeneration*. 2017; 25(5):744-757. <https://doi.org/10.1111/wrr.12590>
- Garten A, Bellingeri A, Weir D et al. Strategies to reduce practice variation in wound assessment and management: the T.I.M.E. Clinical Decision Support Tool. *Wounds International*. 2020. <https://tinyurl.com/39rwpzy9> (accessed 11 March 2024)
- Strohal R, Dissemond J, Jordan O'Brien J, Piaggese A, Rimdeika R, Young T, Apelqvist J. Debridement: an updated overview and clarification of the principle role of debridement. *J Wound Care*. 2013; 22(1):5. <https://doi.org/10.12968/jowc.2013.22.Sup1.S1>
- Tettelbach W, Cazzell S, Reyzelman AM, Sigal F, Caporusso JM, Agnew PS. A confirmatory study on the efficacy of dehydrated human amnion/chorion membrane dHACM allograft in the management of diabetic foot ulcers. *Int Wound J*. 2019; 16(1):19-29. <https://doi.org/10.1111/iwj.12976>
- Wolcott Rd, Kennedy Jp, Dowd Se. Regular debridement is the main tool for maintaining a healthy wound bed in most chronic wounds. *J Wound Care*. 2009; 18(2):54-56. <https://doi.org/10.12968/jowc.2009.18.2.38743>
- Ousey K, Ovens L. Comparing methods of debridement for removing biofilm in hard-to-heal wounds. *J Wound Care*. 2023; 32(S3b):S4-S10. <https://doi.org/10.12968/jowc.2023.32.Sup3b.S4>
- Evans J, Harris C, Jenkins M et al. All Wales guidance for the use of larval debridement therapy. 2013. <https://tinyurl.com/3rv2f9m3> (accessed 11 March 2024)
- Cogo A, Bignozzi AC, Hermans MHE, Quint BJ, Snels JP, Schultz G. A desiccation compound as a biofilm- and necrosis-removing agent: a case series. *J Wound Care*. 2022; 31(10):816-822. <https://doi.org/10.12968/jowc.2022.31.10.816>
- Hermans M. Combining an acidic compound and NPWT: debridement and granulation in leg and foot ulcers. *Ann Case Rep*. 2022. <https://tinyurl.com/44untr3v> (accessed 11 March 2024)
- Bennett E, Bhatt P, Hermans H et al. Tackling hard-to-heal wounds with a new option for chemical debridement. *J Wound Care*. 2023; 32(S3b):S3. <https://doi.org/10.12968/jowc.2023.32.Sup3b.S3>
- Hermans M. Introducing a desiccant debridement agent: as effective as a blade, as easy as a pad. *J Wound Care*. 2023; 32(S3b):S11-S12. <https://doi.org/10.12968/jowc.2023.32.Sup3b.S11>
- Schwarzer S, Radzieta M, Jensen SO, Malone M. Efficacy of a topical wound agent methanesulfonic acid and dimethylsulfoxide on in vitro biofilms. *Int J Mol Sci*. 2021; 22(17):9471. <https://doi.org/10.3390/ijms22179471>
- Guest JF, Deanesi V, Segalla A. Cost-effectiveness of Debrichem in managing hard-to-heal venous leg ulcers in the UK. *J Wound Care*. 2022; 31(6):480-491. <https://doi.org/10.12968/jowc.2022.31.6.480>
- Quan K, Hou J, Zhang Z et al. Water in bacterial biofilms: pores and channels, storage and transport functions. *Cri Rev Microbiol*. 2022; 48(3):283-302. <https://doi.org/10.1080/1040841X.2021.1962802>
- Guest JF, Fuller GW, Vowden P. Cohort study evaluating the burden of wounds to the UK's National Health Service in 2017/2018: update from 2012/2013. *BMJ Open*. 2020; 10(12):e045253. <https://doi.org/10.1136/bmjopen-2020-045253>
- Kalan L SG, Malone M et al. Slough: composition, analysis and effect on healing. 2023. <https://tinyurl.com/45wy8apy> (accessed 11 March 2024)
- Frescos N. Pain assessment tools for chronic lower limb wounds: a scoping review. *Wound Pract Res*. 2019:27-35. <https://doi.org/10.33235/wpr.27.1.27-35>
- Rosenthal D, Murphy F, Gottschalk R, Baxter M, Lycka B, Nevin K. Using a topical anaesthetic cream to reduce pain during sharp debridement of chronic leg ulcers. *J Wound Care*. 2001; 10(1):503-505. <https://doi.org/10.12968/jowc.2001.10.1.26042>
- National Institute for Health and Care Excellence. Lidocaine with prilocaine. 2024. <https://bnf.nice.org.uk/drugs/lidocaine-with-prilocaine/> (accessed 11 March 2024)

# Efficacy and safety of an anti-infection topical desiccating agent (DEBRICHEM) in hard-to-heal wounds

John McRobert, Steven Jeffery and Debbie Delloson

## Abstract

A single centre, non-comparative evaluation was undertaken to observe the clinical results achieved when following best practice for the application of Debrichem. The treatment protocol involved use of this debridement product plus standard of care. The sample comprised 21 patients with complex, non-healing wounds of various aetiologies. One patient dropped out of the evaluation for unknown reasons. Wound types were either venous leg ulcers (n=16) or post-traumatic wounds (n=25). The mean wound duration was 22 months (range: 2 weeks–17 years). Over the 4-week follow-up period, there was a decline in the mean percentage of devitalised tissue present on the wounds, reducing from 69% at baseline to 49% at week 4. Most of the devitalised tissue was slough, for which the mean baseline percentage was 63% compared with an endpoint of 49%. Conversely, the mean percentage of granulation tissue increased from 31% at baseline to 51% at week 4. The mean visual analogue pain score reported during application was 4/10, where 0 represents no pain. However, general wound-related pain scores improved during the follow-up period, with no scores above 2 at week 2, compared with five at baseline. The results indicate that Debrichem is a safe and effective method of debridement that requires minimal training and is single use.

When wounds do not heal with standard care in the expected timeframe, they are classified as hard-to-heal wounds (or variously as stalled, non-healing or chronic wounds). Delays in healing often relate to the wound's primary aetiology, such as ischaemia, venous hypertension or prolonged exposure to pressure, and starting healing first requires effective management or resolution of the underlying issue.

However, healing can also be delayed by the local characteristics of the wound. For example, excess levels of cytokines and proteases can not only degrade the extracellular matrix, but also promote bacterial colonisation and biofilm formation, with increased risk of overt or covert infection.<sup>1</sup> Presence of bacteria and biofilm often manifests in symptoms associated with hard-to-heal wounds, such as increased non-viable (devitalised) tissue and exudate levels, alongside other covert and overt signs of infection (Box 1).<sup>1,2</sup>

Therefore, best practice in hard-to-heal wounds involves not just treating the wound's underlying

aetiology but also implementing effective wound bed preparation (WBP). WBP is multifaceted and addresses several elements, as outlined by the TIMERS framework:<sup>3</sup>

- Tissue
- Infection/inflammation
- Moisture imbalance
- Wound edge
- Regeneration/repair of tissue
- Social factors.

A key step in WBP is debridement: the removal of non-viable tissue from the wound bed and edges. Debridement removes biofilm along with the necrotic and sloughy tissue where it is most likely to proliferate, thus reducing the scope for infection.<sup>1</sup> There is a wide range of debridement methods with varying requirements and results. Surgical and sharp debridement are the gold-standard methods, with the greatest efficacy, but they require specialist training and facilities to perform, which limits their availability.<sup>4</sup>

**John McRobert**, Clinical Director (Research), Pioneer Wound Healing & Lymphoedema Centres

**Steven Jeffery**, Consultant Plastic Surgeon, Pioneer Wound Healing & Lymphoedema Centres

**Debbie Delloson**, Tissue Viability/Research Nurse, Pioneer Wound Healing & Lymphoedema Centre

**Box 1. Signs of infection<sup>1,2</sup>****Overt**

- Erythema (which may present differently depending on the individual's skin tone)
- Local warmth
- Swelling
- Purulent discharge
- Wound breakdown and enlargement
- New or increasing pain
- Increasing malodour

**Covert**

- Hypergranulation
- Bleeding, friable granulation
- Epithelial bridging or pocketing in granulation tissue
- Delayed wound healing beyond expectations
- Increasing exudate
- New or increased pain
- Increasing malodour

Mechanical debridement is selective and accessible to a wide variety of clinicians but less effective than the gold standard.<sup>4</sup> Autolytic debridement using dressings and the body's own mechanisms is much more widely available, but it is less effective than more invasive interventions.<sup>1,4</sup> A common feature of these established forms of debridement is that they all need to be performed regularly or require follow-up with other methods of debridement.<sup>4</sup>

A topical desiccating agent (TDA), marketed as DEBRICHEM (DEBx Medical, Netherlands), is an innovative chemical debridement agent with a rapid desiccant action.<sup>5</sup> TDA requires minimal training to use, and it is currently the only method of debridement designed to be used in a single application, generally not requiring repeat applications, and this could potentially contribute to its cost-efficacy compared with other treatments.<sup>1,6</sup> The desiccant mode of action and the best practice for its use are described in detail elsewhere in this supplement.<sup>7</sup> As yet, published evidence on TDA is in case-series format only.<sup>8-12</sup>

In light of this background, an evaluation was conducted to assess the clinical efficacy and safety profile of TDA in hard-to-heal wounds.

**Aim**

A single-centre non-comparative evaluation was undertaken to observe the results of TDA, when implemented as recommended earlier in this supplement.<sup>7</sup> As a primary objective, it examined the effectiveness of TDA in debriding non-viable tissue and reducing clinical signs of covert or overt infection through a 4-week follow-up period. The secondary objectives were to:

**Box 2. Eligibility criteria for the evaluation****Inclusion criteria**

- Aged 18 years or older
- A complex, non-healing wound of any type or size with stalled progression for at least 4 weeks

**Exclusion criteria**

- Ischaemic wounds
- Untreated vascular aetiology
- Confirmed or suspected neoplastic wound
- Underlying abscesses or fasciitis that require incision and or drainage
- Underlying osteomyelitis requiring bone removal and/or systemic antibiotic treatment
- Known intolerance for or allergy to any of the ingredients of the topical desiccating agent
- Fever (>38°C sublingual, rectal or ear) or suspected sepsis
- Current or planned systemic therapy with antibiotics, corticosteroids, antiangiogenics, cytostatic or immunosuppressive agents
- Pregnant, planning to become pregnant within 24 weeks after the study start date, or breastfeeding

- Assess TDA's safety profile, including patients' pain levels during application
- Establish patients' and clinicians' overall satisfaction with TDA compared with previous treatments.

**Method**

The evaluation was undertaken at an ambulatory outpatient community wound clinic in Sussex, UK, through Pioneer Wound Healing and Lymphoedema Centres. The sample comprised patients who were deemed suitable for TDA application due to suspected presence of biofilm and fulfilled the eligibility criteria given in Box 2. Patients gave their informed consent and were commenced on TDA between 8 and 22 December 2023.

Patients were given standard care according to best practice for their presentation. TDA was applied according to protocol, as detailed earlier in this supplement.<sup>7</sup> First, wound cleansing was performed. Second, because TDA can be painful to apply, patients were offered local anaesthesia with an analgesic cream, as recommended by the manufacturer and according to the judgement of the treating clinician. There is no evidence that an analgesic gel may interfere with TDA's efficacy. After this, TDA was applied.

Data were collected by two senior tissue viability nurses, working together, using a form, consisting largely of numerical and multiple-choice questions. Patient demographic and clinical data were collected at baseline, along with 0–10 visual assessment scale (VAS) pain scores both during initial wound cleansing and subsequently during TDA application (presented

as an increase from baseline general wound-related pain). Comparative data were taken at baseline and at four subsequent weekly follow-ups. At each point, patients were asked to score their general wound-related pain (VAS 0–10). After this, the dressing was removed for assessment, a photograph was taken, and the following outcome measures were recorded:

- Proportion of granulation tissue, necrotic tissue and slough on the wound bed (%), according to the subjective assessment of a senior clinician
- Wound size (cm<sup>2</sup>)
- Exudate level (multiple choice: no exudate, low exudate, medium exudate or high exudate)
- Colour and condition of wound edges (multiple choice: red or pink and flat or raised).
- On completion of the evaluation, any adverse events were noted, and the patient and treating clinician independently rated their overall feeling about TDA compared with previous treatment, where relevant.

The data underwent descriptive analysis, which included calculating the mean, range and standard deviation (SD) of suitable outcomes measures.

As this evaluation was a in-service review, ethics committee approval was not required. The use of a potentially painful product required ethical consideration, and all patients were informed about the potential for high pain levels during application before they gave their informed consent.

## Results

The evaluation included 21 patients, all of whom were included in the analysis. Of the patients, 20 (95%)

completed the full course of treatment and one (5%) was lost to follow-up after week 2, as they stopped attending clinic, with no reason given.

## Patient profile

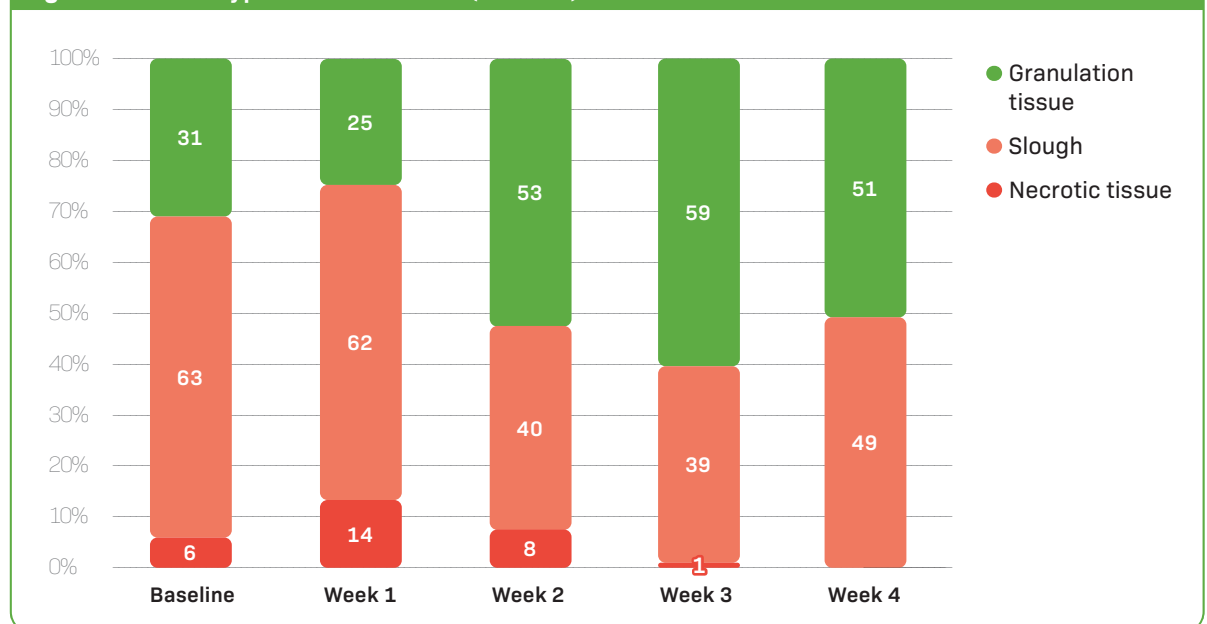
The patients had a mean age of 72 (range 50–90, SD 14) years; 16 (76%) were male and five (24%) were female. The patients had a mean body mass index (BMI) of 32 (range 22–52, SD 9), while 14 (67%) did not smoke, and four (19%) were moderate smokers (5–20 cigarettes a day). Two (10%) had no comorbidities, while 19 (90%) had comorbidities, including anaemia, diabetes, deep vein thrombosis (x4), hypertension (x2), kidney disease, obesity (x2), osteoarthritis, pre-diabetes, psoriasis and rheumatoid arthritis (this list of comorbidities is indicative and not exhaustive). However, these comorbidities were all well controlled.

Of all the patients, 16 (76%) had a venous leg ulcer and five (24%) a non-surgical post-traumatic wound. Of the wounds, 18 (86%) were on the lower leg, two (10%) on the upper leg and one (5%) on the lower arm. The wounds had been present for an average of 22 months (range 2 weeks–17 years). The precise wound duration is not known for two patients, so this was given as the amount of time since their referral to the investigators' centre, but the wound characteristics were consistent with those of complex, non-healing wounds.

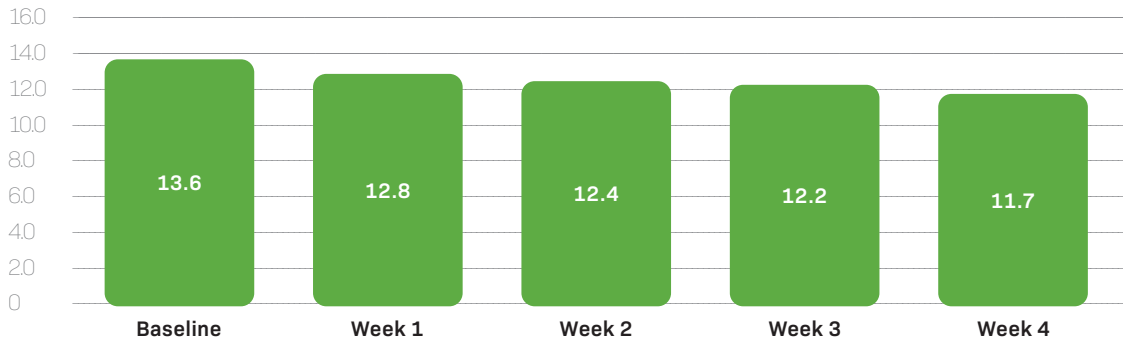
The primary dressings being used to treat these wounds were:

- Acticoat Flex (*n*=4)

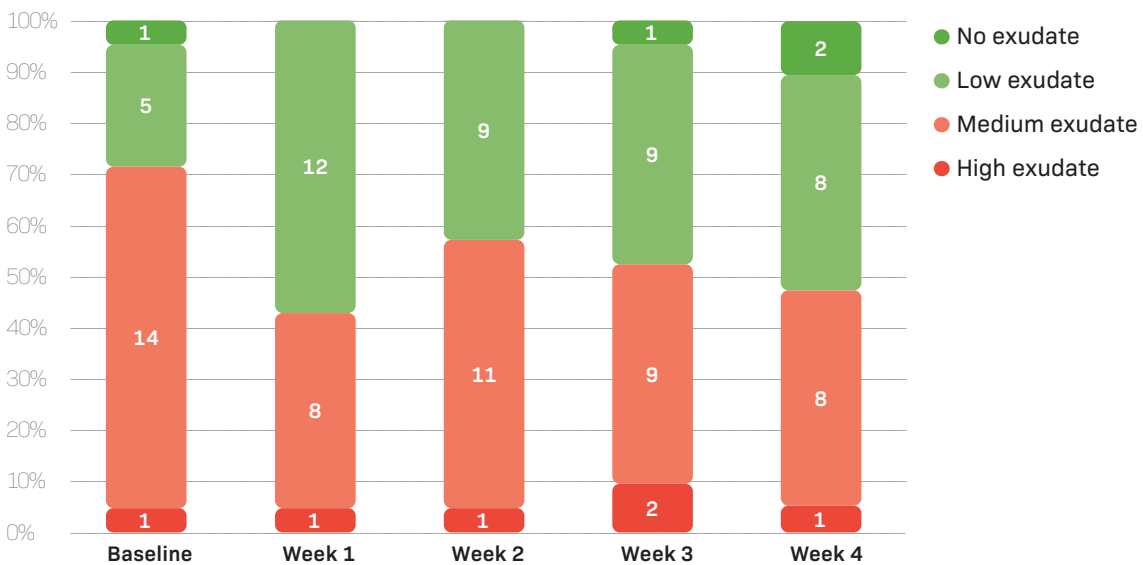
**Figure 1. Tissue types on wound bed (mean %)**



**Figure 2. Wound area (mean cm<sup>2</sup>)**



**Figure 3. Exudate level**



- Allevyn Gentle Border (n=1)
- Aquacel Ag Extra (n=7)
- Aquacel Extra (n=2)
- Atrauman Ag (n=1)
- Inadine (n=2)
- Wound gel (n=4)

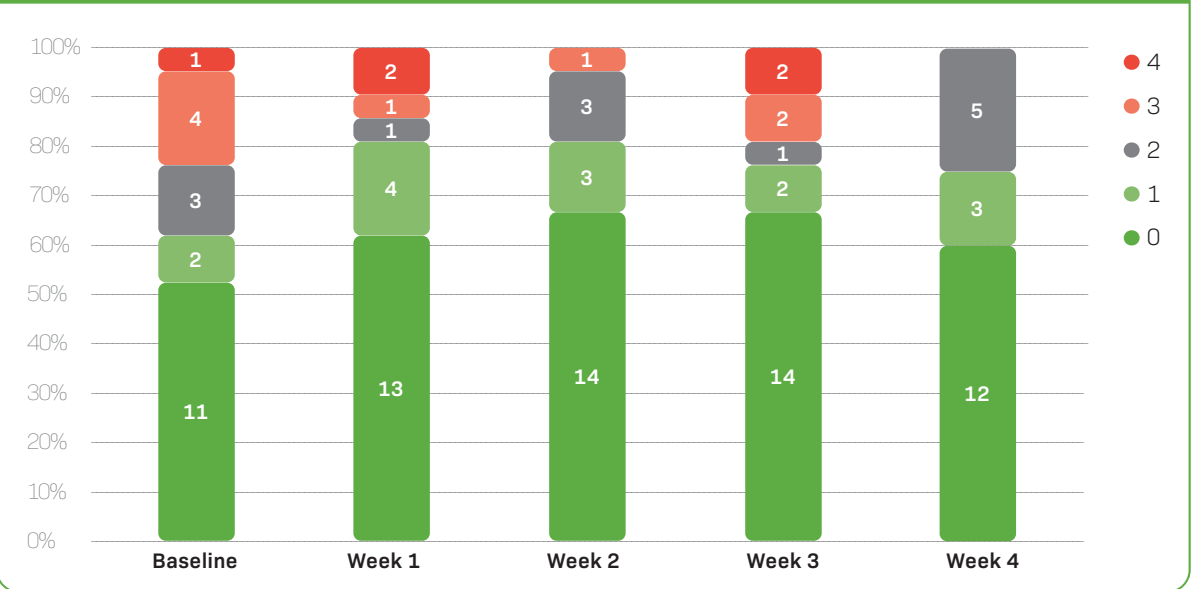
Some dressings were changed over the 4-week period, based on the clinician’s assessment of the patient’s needs. At week 4, the following primary dressings were used, which is indicative of a reduction in use of antimicrobial dressings:

- Acticoat Flex (n=1)
- Aquacel Ag Extra (n=2)
- Aquacel Extra (n=5)
- Atrauman (n=4)
- Atrauman Ag (n=1)
- Inadine (n=2)
- Keracis Fish Skin (n=2)

**Clinical outcomes**

On average, at baseline, the wound beds were covered with 31% granulation tissue (range 0–100, SD 28), 6% necrotic tissue (range 0–80, SD 19) and 63% slough (range 0–100, SD 28). The average amount of granulation tissue had declined slightly by week 1, increased by weeks 2 and 3 and then fell again by week 4. Overall, from baseline to week 4, the percentage covered with granulation tissue had risen to 51% (range 0–100, SD 37), while the amount of slough had declined to 49% (range 0–100, SD 36) and there was practically no necrotic tissue left, at a rounded mean of 0% (range 0–5, SD 1) (Figure 1). The number of patients with 100% granulation tissue increased from one (5%) at baseline to four (20%) by week 4. Over the 4 weeks, on average, the coverage of granulation tissue increased by 20%, representing a 0.7% increase per day.

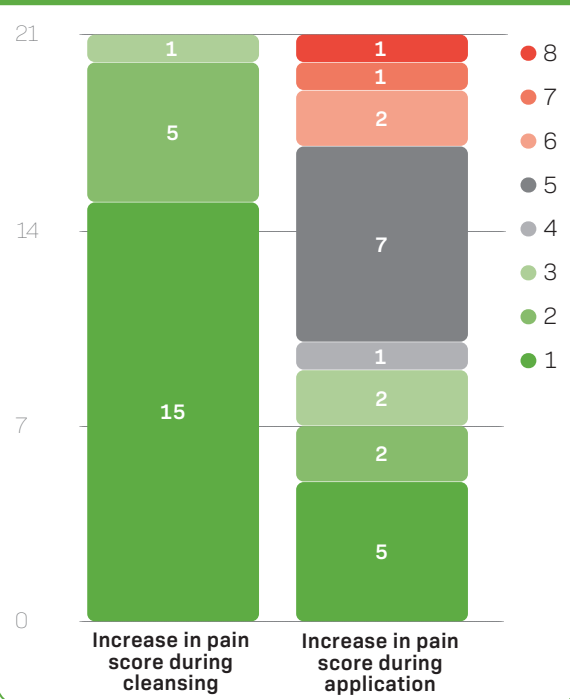
**Figure 4. General wound-related pain (VAS 1–10)**



At baseline, the mean wound area was 13.6cm<sup>2</sup> (range 2–42.9, SD 13.5). This area gradually decreased to 12.8cm<sup>2</sup> (range 2–42.9, SD 13.4) at week 1, 12.4cm<sup>2</sup> (range 1.2–42.9, SD 13) at week 2, 12.2cm<sup>2</sup> (range 1–41.6, SD 12.8) at week 3 and 11.7cm<sup>2</sup> (range 0.2–40.5, SD 13.4) at week 4 (Figure 2). Three patients (14%) experienced an increase in wound size.

At baseline, only one patient (5%) had no exudate, while five (24%) had low exudate, 14 (67%) had medium exudate and one (5%) had high exudate. At week 4, this had reduced, as two (10%) reported no exudate, while eight (38%) had low exudate, another eight (38%) had medium exudate and one (5%) had high exudate (Figure 3). Of the four occurrences of 'no exudate', two coincided with 100% granulation and two with 80% granulation.

**Figure 5. Increase in pain score (VAS 0–10) from general wound-related pain (patients, n)**



The number of patients with red (rather than pink) wound edges began at four (19%) at baseline, but this reduced to three (14%) at week 1, two (10%) at week 2, and one (5%) at week 3 and week 4. The number with raised (rather than flat) wound edges was three (14%) at baseline, and this changed to two (10%) at week 1, three (14%) at week 2, one (5%) at week 3 and week 4.

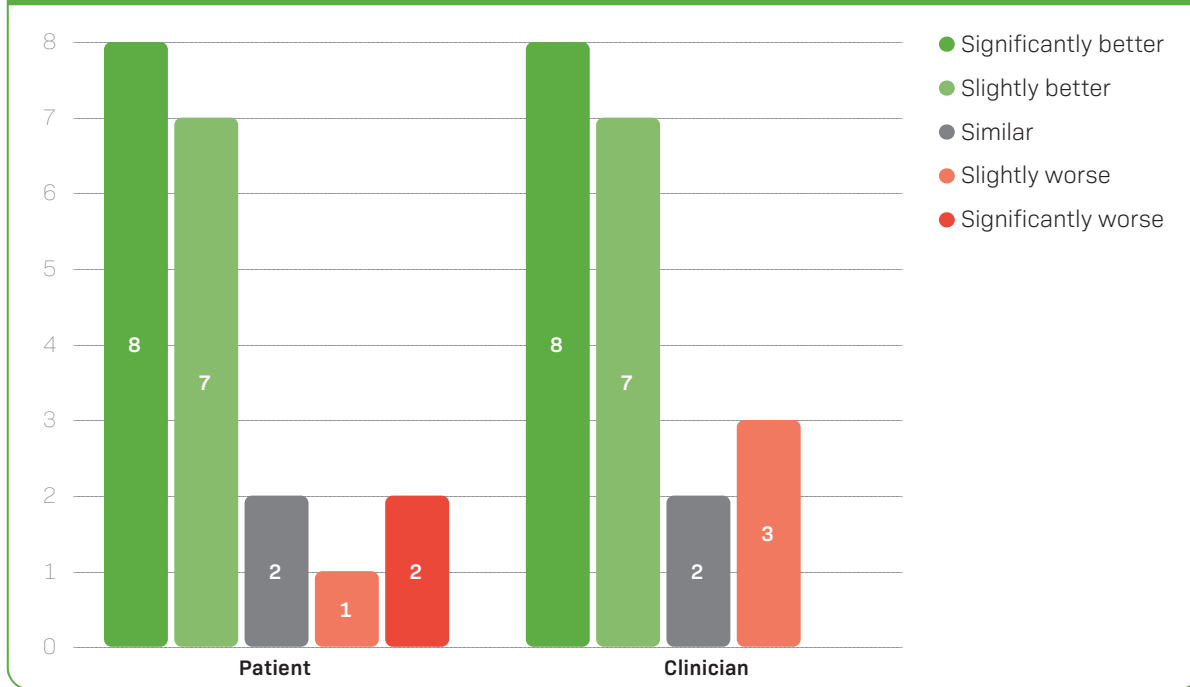
The majority of patients did not experience any general wound-related pain at baseline (n=11, 52%) and through all follow-ups to week 4 (n=12, 57%) (Figure 4). However, at baseline, one patient gave a VAS score for this general pain of 4 (5%) and four others (19%) of 3, while at week 4 no patient gave a VAS above 2. No patient used antibiotics in the 4 weeks after TDA application.

**Safety and satisfaction**

Prior to TDA application, 17 patients (81%) elected to use local anaesthesia and four (19%) declined to do so, of whom one (5%) had neuropathy. The mean level of pain (VAS 0–10) during TDA application was 4 (range 0–10, SD 3). On average, pain during application was greater in those who used anaesthesia, at 4.7 (0–10), compared with those without neuropathy who did not use anaesthesia, at 1.7 (1–4). The increase in VAS pain



**Figure 6. Overall feeling about the desiccant gel compared with previous treatment (patients, n)**



scores, compared with general wound-related pain scores, were greater during TDA application (generally with anaesthesia) than prior wound cleansing (without anaesthesia), as given in *Figure 5*. This increase in pain scores during TDA application is consistent with what would be expected during sharp debridement.

There were no additional applications of TDA after the initial application at baseline (week 0). One patient (5%) experienced a moderate adverse event (a fall at home), which was not related to TDA.

When, at the end of the evaluation, patients were asked to describe their overall feeling about TDA compared with previous treatment, eight (38%) felt it was significantly better, seven (33%) slightly better, two (10%) similar and one (5%) slightly worse (*Figure 6*). When the same question was asked of clinicians, eight (38%) felt it was significantly better, seven (33%) slightly better, two (10%) similar and three (14%) slightly worse.

**Discussion**

**Clinical outcomes**

The most notable clinical outcome was in the relative proportion of the wound bed covered by different tissue types. On average, the amount of the wound bed covered by granulation tissue began at only 31% and had nearly doubled to 59% at week 3, reaching 51% at week 4. Likewise, the number of fully granulated wounds quadrupled from one to four by week 4. The growth of new, healthy and vascularised tissue, often pink or red and bumpy in appearance, suggests that

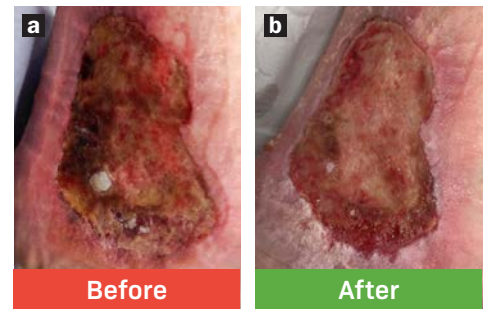
the wounds were entering the proliferation phase of healing. There was an accompanying decline in non-viable tissue, with no necrotic tissue present at all by week 4. This indicates that the product’s desiccant action was effective at debriding non-viable tissue, especially necrotic tissue. These non-viable tissue types are more likely to harbour biofilm and planktonic bacteria, which delay wound healing and can develop into local or systemic infection, necessitating antimicrobial dressings or antibiotic treatment.<sup>13</sup>

The slight temporary increase in visible non-viable tissue at week 2 is likely related to TDA’s mode of action. This form of chemical debridement works by selectively interacting with the non-viable tissue in a way that causes it to dry out, separate from the wound bed and be easily removed. Consequently, the wound bed is likely to become darker and drier before the debridement action is complete and granulation can occur.<sup>8</sup>

There were other clinical signs of infection-free wound healing between baseline and week 4. General wound-related pain scores improved, with a total disappearance of VAS scores above 2 by week 4. There was a small but steady reduction in average wound area week by week (although three patients experienced an overall increase in wound size, suggesting a deterioration in the condition of the wound, which was perhaps due a rebound in microbial growth and may have warranted a second application of TDA). Exudate levels also declined somewhat, from medium or high exudate in most patients at baseline (n=15/21) to no or

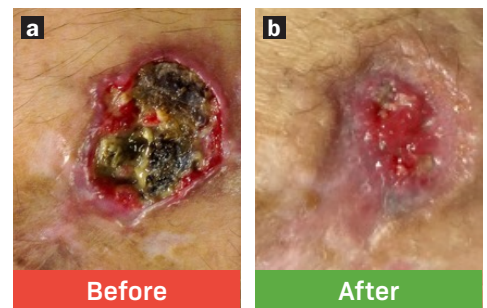
**Figure 7. Venous leg ulcer on the heel before (a) and 4 weeks after (b) treatment with TDA**

The 63-year-old male patient had a history of recurrent infection that had been treated with multiple episodes of antibiotic therapy. The wounds were not responding to usual standard of care, which included weekly sharp debridement, twice weekly wound cleansing, antimicrobial dressings when required and compression bandaging. The patient often asked for debridement to be missed, as they found curettage uncomfortable. The wound had been stalled for 3 years and was heavily colonised. The patient agreed to TDA, which was applied at their regular appointment. At 4 weeks post-application the wound area reduced from 40 cm<sup>2</sup> to 36 cm<sup>2</sup>, and the proportion covered with granulation tissue doubled from 10% to 20%. The wound remained moderately exuding, with flat pink edges. The patient reported that their wound-related pain declined from 4 to 2 on a 0–10 visual assessment scale and that they were sleeping better. The patient felt TDA was significantly better than their previous treatment.



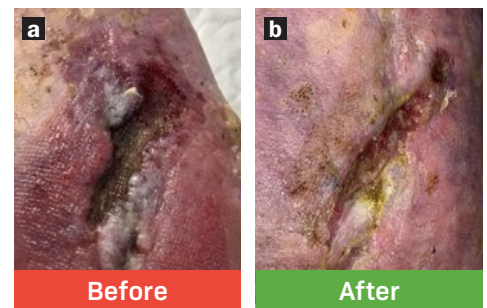
**Figure 8. Traumatic wound on the lower arm before (a) and 4 weeks after (b) treatment with TDA**

The 50-year-old male patient had a history of multiple traumatic wounds that deteriorated quickly and turned necrotic. They were difficult to sharp debride, as this was painful and, because the patient took anticoagulants, sometimes caused profuse bleeding. The patient agreed to TDA as an alternative to sharp debridement at a regular weekly appointment in the community clinic. By the follow-up at week 4, the wound area had reduced from 5.7 cm<sup>2</sup> to 2.9 cm<sup>2</sup>. The proportion of the wound bed covered with granulation tissue had doubled from 5% to 10%, and the necrotic tissue that had covered 80% of the wound bed had completely disappeared, replaced largely with slough. The wound's edges went from red and raised to pink and flat very quickly, and the exudate level reduced from moderate to low. The patient felt TDA was significantly better than their previous treatment. This patient went on to heal fully at week 6, 2 weeks after the end of the evaluation and the second photo.



**Figure 9. Venous leg ulcer before (a) and 4 weeks after (b) treatment with TDA**

The 63-year-old male patient had a 4-year history of longstanding leg ulcers, which had proved difficult to heal with standard of care. The wound was heavily colonised and filled with slough that was very difficult to remove with sharp debridement and very quick to return. TDA was applied after discussion with the patient. The primary dressing used before and throughout treatment was a low-adherent silver. By week 4, the wound area halved from 6 cm<sup>2</sup> to 3 cm<sup>2</sup>, and the proportion covered with granulation tissue increased from 40% to 50%. There was less wet, thick and adherent slough. The wound's edges remained flat but went from red to pink, and the exudate level reduced from moderate to low. The patient's overall wound-related pain declined from 1 to 0 on a 0–10 visual assessment scale. The patient felt TDA was slightly better than their previous treatment.



low exudate in most at week 4 ( $n=10/19$ ), with low exudate being optimal for moist wound healing and no exudate in these cases reflecting complete or near complete granulation. From the start to the end of the evaluation, more wound edges were flat or pink, suggesting an overall increase in epithelialisation.

The overall picture is that application of TDA in wounds stalled for an average of 22 months was followed by a reduction of non-viable tissue, which is likely to harbour biofilm,<sup>13</sup> and other signs of a restarted healing process, although full healing would take longer than the 4-week evaluation period to complete. This is illustrated in greater detail with three cases, selected as typical indicative examples, given in *Figures 7–9*. Other case series suggest that wounds treated with TDA are likely to fully granulate within

weeks of application. In one earlier case series, 50 of 54 (92.5%) wounds treated with TDA reached full granulation in an average of 36.2 days (range 2–131 days).<sup>10</sup> In another case series, all ( $n=12$ ) hard-to-heal wounds treated with TDA and consecutive negative pressure wound therapy (NPWT) reached complete granulation, which took an average of 13.2 days (range 7–21 days).<sup>11</sup>

#### Safety and satisfaction

TDA is a powerful acid intended to desiccate non-viable tissue for easy removal, and thus it is unsurprising that many patients experienced increased pain during its application. There was a notably greater increase from general wound-related pain than that caused by wound cleansing, suggesting that TDA's chemical action

causes pain additional to that caused by manipulation of the wound. However, this pain score is comparable to that caused by sharp debridement.<sup>14,15</sup> Moreover, the pain scores reported were lower on average than those reported by many patients in an earlier case series, in which analgesics were generally not used.<sup>8</sup> This suggests that the application of anaesthetic cream prior to using TDA, as was the case in all sensate patients in this evaluation, is an effective way to control pain levels, and there is no evidence that this impacts the efficacy of the desiccant action. The wide range of pain levels reported is likely related to the variable degree of sensation in different wounds for different people, especially as the few patients who did not use anaesthesia reported comparatively little pain.

It is important to note that TDA's application only lasts up to 60 seconds, after which the chemical is washed off with sterile water or saline, and the pain rapidly diminishes.<sup>8</sup> Patients' largely positive overall feeling about TDA suggests that they considered this short-term pain to be a price worth paying for the longer-term benefits they perceived. This was stated explicitly by patients in an earlier case series.<sup>8</sup> Such positive feelings were likely influenced by the improvements in clinical signs of healing, but there may have also been an appeal to the simplicity and speed of the process of applying TDA. Likewise, the tangible sight of non-viable tissue drying up and sloughing off may have given clinicians and patients a sense of progress in wounds that had been hard to heal for often months or years, particularly in the majority of patients who experienced improvement.

Patients and clinicians gave very similar scores for their overall feeling about TDA compared with previous treatment. This suggests there was some alignment between the clinicians' and patients' expectations and observations. The alignment was not only in the aggregate, as, in the two instances of patients who found TDA to be significantly worse, the clinicians also made a negative assessment. It was the opinion of the assessing nurses that the wound had not progressed any further with the use of TDA.

### Limitations

The applicability of this data is limited by a relatively small sample size and absence of a control group, such as another form of debridement, for direct comparison. The inclusion of a range of different wound types introduced additional variables. Likewise, the use of a variety of dressings and the changing of these through the evaluation period created an additional variable that may have affected the results. Also, the full wound duration was not known for two patients presenting with complex, non-healing wounds. The weekly intervals between follow-ups were approximate rather than precise 7-day intervals. One patient was lost to follow-up.

### Conclusion

The results of this evaluation suggest that TDA is a safe and effective debridement tool. Compared with other debridement options, TDA has the advantages of requiring minimal training and only a single application. It can be applied in ambulatory settings and outpatient clinics, obviating the need for specialist facilities and hospital admission. Moreover, it can be applied in patients on anti-coagulation therapy. This combination of safety, efficacy and convenience makes TDA a valuable option in WBP for hard-to-heal wounds, where there is a need to remove non-viable tissue and biofilm and reduce the risks of biofilm re-formation and local infection, in order to restart the healing process.

### References

- Swanson T, Ousey K, Haesler E et al. IWII wound infection in clinical practice consensus document: 2022 update. *J Wound Care*. 2022; 31(S12):S10–S21. <https://doi.org/10.12968/jowc.2022.31.Sup12.S10>
- Schultz G, Bjarnsholt T, James GA et al. Consensus guidelines for the identification and treatment of biofilms in chronic nonhealing wounds. *Wound Repair and Regeneration*. 2017; 25(5):744–757. <https://doi.org/10.1111/wrr.12590>
- Atkin L, Bučko Z, Conde Montero E et al. Implementing TIMERS: the race against hard-to-heal wounds. *J Wound Care*. 2019; 23(S3a):S1–S50. <https://doi.org/10.12968/jowc.2019.28.Sup3a.S1>
- Strohal R, Dissemmond J, Jordan O'Brien J et al. Debridement: an updated overview and clarification of the principle role of debridement. *J Wound Care*. 2013; 22(1):5. <https://doi.org/10.12968/jowc.2013.22.Sup1.S1>
- Schwarzer S, Radzieta M, Jensen SO, Malone M. Efficacy of a topical wound agent methanesulfonic acid and dimethylsulfoxide on in vitro biofilms. *Int J Mol Sci*. 2021; 22(17). <https://doi.org/10.3390/ijms22179471>
- Guest JF, Deanesi V, Segalla A. Cost-effectiveness of Debrichem in managing hard-to-heal venous leg ulcers in the UK. *J Wound Care*. 2022; 31(6):480–491. <https://doi.org/10.12968/jowc.2022.31.6.480>
- Bhatt P, Sharpe A, Staines K, Whithers A. Topical desiccating agent (DEBRICHEM): an accessible debridement option for removing biofilm in hard-to-heal wounds. *J Wound Care*. 2024; 33(S5b):S4–S9
- Bennett E, Bhatt P, Hermans H et al. Tackling hard-to-heal wounds with a new option for chemical debridement. *J Wound Care*. 2023; 32(S3b):S3. <https://doi.org/10.12968/jowc.2023.32.Sup3b.S3>
- Algharib A, van Dortmont LMC, Hendrix MGR, Riedel S, Möller R, Koning GG. Innovative biochemisurgical treatment for stabilisation of an end-stage chronic wound in a complex vascular compromised patient. *Int J Surg Case Rep*. 2024; 114:109103. <https://doi.org/10.1016/j.ijscr.2023.109103>
- Cogo A, Bignozzi AC, Hermans MH, Quint BJ, Snels JP, Schultz G. A desiccation compound as a biofilm- and necrosis-removing agent: a case series. *J Wound Care*. 2022; 31(10):816–822. <https://doi.org/10.12968/jowc.2022.31.10.816>
- Cogo A, Quint BJ, Bignozzi CA. Restarting the healing process of chronic wounds using a novel desiccant: a prospective case series. *Wounds*. 2021; 33(1):1–8
- Hermans M. Combining an acidic compound and NPWT: debridement and granulation in leg and foot ulcers. *Ann Case Report*. 2022; 7. <https://doi.org/10.29011/2574-7754.101101>
- Kalan L, Schultz G, Malone M et al. Slough: composition, analysis and effect on healing. 2023. <https://tinyurl.com/45wy8apy> (accessed 11 March 2024)
- Rosenthal D, Murphy F, Gottschalk R, Baxter M, Lycka B, Nevin K. Using a topical anaesthetic cream to reduce pain during sharp debridement of chronic leg ulcers. *J Wound Care*. 2001; 10(1):503–505. <https://doi.org/10.12968/jowc.2001.10.1.26042>
- Martínez-Monsalve A, Selva-Sevilla C, Gerónimo-Pardo M. Analgesic effectiveness of topical sevoflurane to perform sharp debridement of painful wounds. *J Vasc Surg*. 2019; 69(5):1532–1537. <https://doi.org/10.1016/j.jvs.2018.08.175>

# DEBRICHEM®



1

## REMOVES BIOFILM & INFECTION

DEBRICHEM® removes the biofilm and infection in a 60 second application. Triggering **fast granulation and promoting natural healing.**

2

## SINGLE APPLICATION

DEBRICHEM is certified as a **single use medical device (IIb)**. Clinical **results show** that after a single DEBRICHEM application **>90% of wounds start healing.**

3

## EASY AND FAST TO USE

Due to its fast action and applicability **outside the surgery room**, DEBRICHEM® can easily be integrated within standard wound care procedures.

4

## SAFE ON INTACT SKIN

DEBRICHEM® works by withdrawing water from the wound bed. Due to the low water content of the outer layer of the epidermis, the surrounding **healthy skin is not affected.**